




*This publication is distributed by Soft Bones Inc.,
A U.S. Hypophosphatasia Foundation.*



Hypophosphatasia:
An Overview

Michael P. Whyte, M.D.



Definition of hypophosphatasia (HPP)

Hypophosphatasia (HPP) is the rare genetic form of rickets or osteomalacia that features paradoxically low serum alkaline phosphatase (ALP) activity.

Classification

Six clinical forms represent a useful classification of HPP.

1. Perinatal Hypophosphatasia
2. Infantile Hypophosphatasia
3. Childhood Hypophosphatasia
4. Adult Hypophosphatasia
5. Odontohypophosphatasia
6. Benign Prenatal Hypophosphatasia

The expression (disease severity) of HPP ranges greatly with the clinical consequences spanning death *in utero* from an essentially unmineralized skeleton to problems only with teeth during adult life. The patient's age at which bone disease becomes apparent distinguishes the perinatal, infantile, childhood, and adult forms. Those who exhibit only dental manifestations have odonto-HPP. The benign prenatal form of HPP is the newest group and manifests skeletal deformity *in utero* or at birth, but in contradistinction to perinatal HPP is clearly more mild and shows significant spontaneous postnatal improvement.

■ Clinical Features

1. Perinatal Hypophosphatasia

This is the most severe form of HPP, and is almost always fatal. It manifests in utero and can cause stillbirth. At delivery, limbs are shortened and deformed and there is caput membraneum from profound skeletal hypomineralization. Unusual osteochondral spurs may pierce the skin and protrude laterally from the midshaft of the ulnas and fibulas. There can be a high pitched cry, irritability, periodic apnea with cyanosis and bradycardia, unexplained fever, anemia, and intracranial hemorrhage. Some affected neonates live a few days, but suffer increasing respiratory compromise from defects in the thorax and hypoplastic lungs. Very rarely is there long-term survival.

2. Infantile Hypophosphatasia

Infantile HPP presents postnatally, but before age 6 months. Development may seem normal until there is poor feeding, failure to thrive, hypotonia, clinical signs of rickets, or seizures. The cranial sutures feel wide, but this is from diminished ossification of the skull. There may be bulging of the anterior fontanel, raised intracranial pressure with papilledema, proptosis, and brachycephaly. Sclerae may be blue. A flail chest that predisposes to pneumonia can occur from rachitic deformity of the thorax and rib fractures. Weakness and delayed motor milestones are important complications. Exceptional patients manifest vitamin B6-dependent epilepsy before skeletal disease. If the patient survives infancy, true bony fusion of cranial sutures may occur prematurely. Hypercalcemia and hypercalciuria are common, and can cause recurrent vomiting, nephrocalcinosis, and renal compromise.

Although somewhat less severe than in the perinatal form of HPP, the radiographic changes of infantile HPP are also pathognomonic. Sometimes there is an abrupt transition from normal diaphyses to poorly calcified metaphyses. Sequential radiographic studies may disclose persistence of defective skeletal mineralization (rickets), but also gradual demineralization of the skeleton. Then, fractures and bone deformities manifest. Skeletal scintigraphy can suggest functional closure of cranial sutures if decreased radioisotope uptake occurs at these structures that appear “widened” radiographically. Functional craniosynostosis can occur despite widely “open” fontanels that are an illusion from the hypomineralized calvarium.

■ Clinical Features (contd.)

3. Childhood Hypophosphatasia

Childhood HPP is also quite variable in severity but diagnosed after 6 months of age. Premature loss of deciduous teeth (i.e. < age 5 years) occurs painlessly without tooth root resorption because little cementum covers the root. “Baby” teeth “slide” out without bleeding, and strikingly with root intact. Mandibular then maxillary incisors are lost first, but occasionally radiographs of all teeth may show enlarged pulp chambers and root canals (“shell teeth”). Rachitic deformities can include beading of the costochondral junction, bowed legs or knock-knees, enlargement of wrists, knees and ankles, and occasionally a brachycephalic skull.

The rickets can cause short stature and delayed walking. There may be skeletal pain and stiffness, as well as episodes of joint discomfort and swelling. Rarely, a painful syndrome involving bone marrow edema occurs that mimics osteomyelitis or malignancy. Typically, patients have muscle weakness consistent with a nonprogressive myopathy that often features a waddling gait. However, unlike infantile HPP, childhood HPP does not cause vitamin B6-dependent seizures. Although the prognosis for the permanent dentition is better, poorly characterized problems later often lead to tooth loss and denture wearing in adult life. Radiographs of the major long bones usually reveal characteristic focal defects of cartilage that project from the growth plates into the metaphyses. These are often described as “tongues” of radiolucency. This can distinguish HPP from other forms of rickets and metaphyseal dysplasias. There can also be irregularity of the provisional zone of calcification, metaphyseal flaring with areas of radiolucency adjacent to areas of osteosclerosis, and sometimes physeal widening. Premature bony fusion of all cranial sutures (craniosynostosis) can cause raised intracranial pressure, proptosis, and cerebral damage. Then, the calvarium has a diffuse “beaten-copper” appearance.

Clinical Features (contd.)

4. Adult Hypophosphatasia

Adult HPP usually presents during middle age. However, some patients recall rickets or premature loss of deciduous teeth. Then, following good health in early adult life, they have painful feet caused by recurrent, poorly-healing, metatarsal stress fractures. Subsequently, there can be discomfort in the hips or thighs due to femoral pseudofractures. Widespread and non-healing fractures may then cause significant debility. Early loss or extraction of the adult dentition is not uncommon. Calcium pyrophosphate dihydrate (CPPD) deposition can cause PPI arthropathy, and occasionally pseudogout. This complication reflects increased endogenous levels of PPI. There may also be seemingly paradoxical deposition of hydroxyapatite crystals, and ossification of ligaments resembling spinal hyperostosis. Rarely, primary hyperparathyroidism is reported. Radiographs often show pseudofractures, a hallmark of osteomalacia. Radiographs may also reveal generalized osteopenia and chondrocalcinosis, and sometimes the features of PPI arthropathy or calcific peri-arthritis.

5. Odontohypophosphatasia

This mildest form of HPP is diagnosed when the only apparent clinical abnormality is dental disease. Here, there is no radiographic or bone biopsy evidence of HPP skeletal disease.

6. Benign Prenatal Hypophosphatasia

Several reports characterized HPP patients who manifested bowing deformity in utero, but whose postnatal courses featured spontaneous skeletal improvement. This is not an uncommon form of HPP, and is sometimes referred to as “bent but not broken” HPP. Autosomal recessive (AR) as well as autosomal dominant (AD) inheritance of a variety of TNSALP mutations can be the cause. Skeletal deformity of these affected fetuses can improve during later stages of pregnancy. However, HPP outcome, when skeletal deformity is detected early in utero by ultrasound, is not predictable by this technique.

Diagnosis

■ Laboratory Findings

Biochemical

ALP ACTIVITY

HPP can be diagnosed with confidence when the clinical history, physical findings, and radiographic changes are consistent with this disorder and occur with serum ALP activity that is clearly subnormal for the patient's age. In general, the more severe and obvious the HPP the lower the serum ALP activity compared to reference values appropriate for age. Even patients with odonto-HPP are hypophosphatasemic. In the perinatal and infantile forms of HPP, low serum ALP activity is detectable at birth in serum from umbilical cord blood. Notably, in forms of rickets or osteomalacia other than HPP, serum ALP activity is typically increased. Hence, the hypophosphatasemia of HPP seems paradoxical and is especially striking. Nevertheless, several diagnostic pitfalls must be avoided. Blood for serum ALP assay must be collected properly. Chelation of Mg^{2+} or Zn^{2+} by ethylenediamine tetra-acetic acid (EDTA) will destroy ALP activity. Furthermore, levels of serum ALP activity should be interpreted knowing that reference ranges differ significantly depending on patient age and gender. Healthy infants, children, and adolescents have considerably higher serum ALP levels compared to adults (reflecting an abundance of the bone isoform of TNSALP). Also, the especially high serum ALP activity of the growth spurt of adolescence occurs earlier in girls than in boys. Although the problem is now greatly improved, reference ranges cited by some clinical laboratories still report ALP values for adults exclusively. Sometimes, the lower limit of normal is even given as zero, perhaps because clinicians typically concern themselves with elevated values to detect and to follow other skeletal or hepatobiliary diseases. Consequently for some infants or children, the diagnosis of HPP is missed because they are incorrectly considered to have normal serum ALP levels, or are perhaps erroneously diagnosed with pseudo-HPP because the appropriate higher pediatric reference range is not recognized.

Laboratory Findings (contd.)

ALP ACTIVITY (contd.)

Also, hypophosphatasemia may occur in a variety of disorders, and with exposure to certain drugs (glucocorticoids, chemotherapy, clofibrate, vitamin D toxicity, or milk-alkali syndrome), as well as with massive transfusion of blood or plasma, or radioactive heavy metal poisoning. However, these clinical situations should be readily apparent and diagnosed. Rarely, newborns with severe osteogenesis imperfecta (type II) can have low serum ALP activity, as do some patients with RUNX2 (CBFA1) deactivation causing cleidocranial dysplasia from quiescent osteoblast function. To assess these “hypophosphatasemias” vis-à-vis HPP, assay of plasma PLP (“vitamin B6”) can help. Elevated PLP levels are expected only for HPP, in which all TNSALP isoenzyme activity (including liver), not just bone, is reduced. Finally, a few case reports of HPP describe transient increases in serum ALP activity (probably the bone isoform of TNSALP) after orthopedic surgery or fracture. In theory at least, those conditions that increase circulating levels of any type of ALP (e.g. pregnancy, hepatobiliary disease) could mask the biochemical diagnosis of HPP. Accordingly, if a puzzling patient is encountered, documentation that serum ALP activity is, or once was, low on more than one occasion seems advisable. Quantitation of the levels of serum ALP isoenzymes, or specifically the bone TNSALP isoform, may also be helpful in exceptional circumstances (e.g. pregnancy, certain malignancies). Now, however, mutational analysis of the TNSALP gene is available from research and fee-for-service laboratories.

■ Laboratory Findings (contd.)

Biochemical

MINERALS

In contrast to nearly all types of rickets or osteomalacia, in HPP serum calcium or Pi levels are not low. The pathogenetic block of mineral entry into the skeleton caused by extracellular accumulation of P_{PPi} instead leads to a unique disturbance of calcium and Pi homeostasis that is particularly apparent at the severe end of the HPP spectrum. In the infantile form of the disease, hypercalcemia occurs frequently, and serum parathyroid hormone (PTH) levels can be suppressed and associated with hyperphosphatemia. Hypercalciuria is expected in this circumstance. In childhood HPP, only exceptional patients have mild hypercalcemia, but hypercalciuria is relatively common. Serum levels of 25-hydroxyvitamin D and 1,25-dihydroxyvitamin D are typically unremarkable but, when there is hypercalcemia, serum PTH and 1,25-dihydroxyvitamin D levels are low. Subnormal circulating levels of PTH sometimes occur with hypercalciuria alone. This finding has been attributed to an abnormality in the Ca²⁺-PTH feedback system but, instead, the observation seems predictable from the disruption in mineral homeostasis. Years ago, several HPP patients reportedly had elevated serum PTH levels, but renal compromise from hypercalcemia with retention of immunoreactive PTH fragments may have been the explanation. Patients with the childhood and adult forms of HPP are typically eucalcemic, but have serum Pi levels that are above the mean value for age-matched controls, and approximately 50% of these individuals are distinctly hyperphosphatemic. Enhanced renal reclamation of phosphorus (increased tubular maximum for P/glomerular filtration rate; i.e. T_{mP}/GFR) explains this finding, which is only sometimes accompanied by a suppressed circulating level of PTH. Hence, it is possible that TNSALP plays a positive role (or urinary P_{PPi} a negative role) in renal excretion of Pi. Indeed, patients with generalized arterial calcification of infancy, GACI (OMIM #208000) caused by low extracellular levels of P_{PPi}, can develop hypophosphatemia and rickets. Inexplicably, especially rare “HPP” patients have been reported who are hypophosphatemic from renal Pi wasting, but *TNSALP* mutation studies were not yet possible to document their HPP.

Laboratory Findings (contd.)

ROUTINE STUDIES

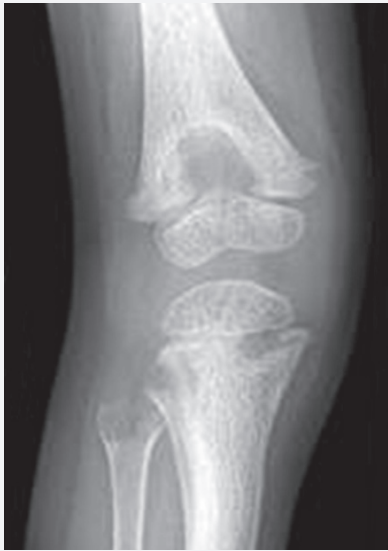Other routine biochemical tests, including serum parameters of liver or muscle function (e.g., bilirubin, aspartate aminotransferase, lactate dehydrogenase, creatine kinase, aldolase), are unremarkable in HPP. Serum acid phosphatase activity is generally normal, but osteoclast-derived tartrate-resistant acid phosphatase was inexplicably elevated for more than a decade in one affected woman. Increased levels of proline in blood and urine have been described in a few patients, but the significance is not known. Bone turnover markers have not yet been detailed in published reports.

TNSALP NATURAL SUBSTRATES

Elevated levels of phosphoethanolamine (PEA) in blood or urine, typically measured in “inborn error” laboratories that use quantitative amino acid chromatography and now also provided specifically by a few commercial laboratories, support a diagnosis of HPP. However, phosphoethanolaminuria is not pathognomonic of HPP and can occur in other disorders, including several metabolic bone diseases. Ideally, a 24-hour urine collection is assayed and the PEA level is “normalized” to the creatinine content. Importantly, PEA excretion in urine is conditioned by subject age and diet, follows a circadian rhythm, and can be normal in individuals with mild HPP. The following age-adjusted reference ranges, expressed as micromoles of PEA per gram of urine creatinine, have been published (<15 years, 83–222; 15–30 years, 42–146; 31–41 years, 38–155; and >45 years, 48–93). Compared to serum or urine levels of PEA, an increased plasma level of pyridoxal 5'-phosphate (PLP) seems to be a more sensitive and specific marker for HPP. Commercial assays are readily available, typically ordered as “vitamin B6”.

Diagnosis

■ Radiological Findings



The right knee of a 2-year-old girl with childhood HPP shows characteristic “tongues” of radiolucency in all metaphyses. Metaphyseal irregularity is especially prominent in the head of the fibula.

Radiographic survey of the skeleton reveals pathognomic changes in perinatal and infantile HPP and at the severe end of the spectrum for childhood HPP. The findings in adult HPP will rarely suggest the disorder, unless there are characteristic metatarsal stress fractures together with femoral pseudofractures. However, these changes in adults are not diagnostic.

Radiographs of the skeleton when HPP is severe show pathognomonic findings distinguishable from even the most severe cases of osteogenesis imperfecta and other forms of congenital dwarfism. Nevertheless, the features can be diverse, and with considerable patient-to-patient variation. In some cases, bones appear completely unmineralized. If skeletal mineralization is present, severe rachitic changes can be apparent. Parts of (or entire) vertebrae may appear to be missing. The findings can also include poorly ossified epiphyses together with irregular extensions of radiolucency into metaphyses (and sometimes cortical bone spurs). Fractures are often

present. Bones of the cranium may show calcification only centrally, giving the illusion that the sutures are widely separated. However, these sutures can be functionally “closed”. The teeth are poorly formed.

Bone scanning can reveal fractures, and may help to detect craniosynostosis. Magnetic resonance imaging is necessary to identify the unusual occurrence of a painful bone marrow edema syndrome in HPP that can resemble chronic recurrent multifocal osteomyelitis or malignancy. Dual energy x-ray absorptiometry (DXA) in HPP may be difficult to interpret when there are heterogeneous skeletal changes of bone mineralization, patient deformity, or short stature.

Diagnosis (contd.)

■ Histopathological Findings

Skeleton

Except in odonto-HPP, bone biopsy shows defective skeletal mineralization. This includes excesses of unmineralized skeletal matrix (osteoid) that can occur in a patchy distribution. The impaired skeletal mineralization is confirmed when fluorescence microscopy fails to show sufficient numbers of discrete fluorescent bands on bone surfaces after the patient is administered tetracycline. Unmineralized osteoid accumulates in HPP because it does not calcify properly. However, features of secondary hyperparathyroidism are typically absent in HPP, but common in rickets or osteomalacia when there is hypocalcemia. In the physes (growth plates), rachitic changes can include disruption of the normal columnar arrangement of chondrocytes, widening of the zone of provisional calcification, and failure of primary spongiosa to calcify near degenerating cartilage cells. However, the sources of the bone isoform of TNSALP (chondrocytes and osteoblasts) are present, although with reduced TNSALP activity. The severity of the mineralization defect in HPP generally reflects the clinical outcome. Cranial “sutures” that appear widened on radiographs are not fibrous tissue, but are an illusion due to hypomineralization of the calvarial bones.

Patchy excesses of osteoid on trabecular bone surfaces appear to be a feature of the mineralization defect of HPP in children as well as in adults. ALP activity in bone tissue correlates inversely with the degree of osteoid accumulation.

Electron microscopy of perinatal and infantile HPP bone obtained at autopsy has revealed findings consistent with the extracellular accumulation of PPI in HPP.

Diagnosis (contd.)

■ Histopathological Findings (contd.)

Dentition

Premature loss of deciduous teeth occurs in several disorders (including toxicities, metabolic errors, and malignancies). In HPP, this complication results from lack of acellular cementum covering tooth roots. The magnitude of this defect varies from tooth to tooth, but the number of teeth lost prematurely generally reflects the severity of the skeletal disease. Incisors are most vulnerable. Big pulp chambers in HPP suggest retarded dentinogenesis. The excessive width of predentin, increased amounts of interglobular dentin, and impaired calcification of cementum seem analogous to the osteoidosis observed in bone. Conflicting reports discuss whether enamel is directly compromised. Desiccated deciduous teeth may still be useful for microscopic examination. The histopathological changes of HPP found in the permanent teeth seem similar, but relatively mild, compared to the deciduous teeth.



Prognosis

Prior to the promising experience emerging from experimental, bone-targeted, TNSALP-replacement therapy for HPP, perinatal HPP was almost always rapidly fatal. Hence it is critical that perinatal HPP be distinguished from benign prenatal HPP that shows spontaneous improvement after birth. Infantile HPP has an unpredictable outcome when the patient is first evaluated. In some babies, progressive skeletal deterioration occurs and leads to death within a few months. In others, there is significant spontaneous improvement. Others may suffer from persisting rachitic disease, eventually including premature craniosynostosis. Once there is a diagnosis of infantile HPP, sequential clinical assessments and radiographic studies are critical for prognostication. Although the precise likelihood is not known, perhaps 50% of patients with infantile HPP die from respiratory compromise and pneumonia that follows worsening skeletal disease of the chest. In others, there may be significant improvement, particularly after infancy, perhaps because growth rates decrease and thereby residual TNSALP levels become more effective in mineralizing the skeleton.

Indeed, a preliminary report in 1986 from Canada suggested that the adult stature of survivors of infantile HPP can be normal, but there are significant exceptions both there and in the USA. Childhood HPP may also seem to improve spontaneously when growth plates fuse in young adult life, but recurrence of symptoms and complications later is possible, if not likely. Adult HPP is a chronic bone disease after the onset of symptomatology. Worsening osteomalacia, leading to pain and fractures, can occur at menopause in affected women, but does not seem preventable by estrogen replacement therapy).

Treatment

■ Supportive Care

Severely affected infants and young children with HPP should be followed carefully to detect neurological complications, such as increased intracranial pressure, from either “functional” or “true” craniosynostosis. Functional craniosynostosis can occur despite the radiographic illusion of widely open fontanelles, and may require craniotomy. In other circumstances, skull deformity may occur but without significant neurological sequelae.

Vitamin B6-dependent seizures manifest only in severe HPP (perinatal or infantile forms) and represent a grave prognostic sign, probably because TNSALP deficiency must be especially profound to cause the biochemical disturbance that explains this complication, and thus there will also be severe skeletal disease.

Symptoms from CPPD or calcium phosphate crystal deposition may respond to non-steroidal anti-inflammatory medication. One report suggests that naproxen is useful for the discomforts of children with HPP, including during the syndrome of painful bone marrow edema.

■ Surgical Treatment

Fractures in children with HPP do mend, although delayed healing seems likely and has occurred after femoral osteotomy with casting. In adult HPP, proximal femoral pseudofractures may remain unchanged for years, but will not unite unless treated prophylactically with intramedullary fixation, or they first progress to complete fractures. Use of load-sharing intramedullary rods or nails, rather than load-sparing plates, etc., seems best for prophylactic or acute surgical management of pseudofractures or acute femoral fractures. For recurrent metatarsal stress fractures, ankle-foot orthoses may be useful.

Treatment (contd.)

■ Dental Treatment

Expert dental evaluation and care is important for HPP. In HPP children, severely compromised dentition can impair speech and nutrition, and preservation of teeth in position or use of complete or partial dentures may be necessary.

■ Medical Treatment

There is no established medical therapy for HPP, although a variety of treatments have been attempted. Traditional regimens for rickets and osteomalacia (vitamin D and mineral supplements) should be avoided, unless deficiencies are documented, because circulating levels of calcium, Pi, and the vitamin D metabolites are typically not low. In infantile HPP, excessive vitamin D or mineral supplementation could provoke or exacerbate the hypercalciuria and hypercalcemia that is often encountered in severe HPP. On the other hand, restriction of vitamin D intake or sunshine exposure should be avoided, because superimposed vitamin D-deficiency rickets has occurred in HPP.

Hypercalcemia in infantile HPP can be improved by lowering dietary calcium intake and/or with hydration, loop diuretics, or glucocorticoid therapy. Progressive skeletal demineralization may follow, but is probably due to the HPP *per se* if serum levels of calcium and Pi do not become low. Bisphosphonates could be harmful in HPP because they are analogs of PPI, lower bone turnover, and can inhibit ALPs by binding Zn²⁺ and Mg²⁺.

In 1996, preliminary findings in the *TNSALP* gene knockout mouse supported marrow cell transplantation as a means to increase directly ALP activity near skeletal matrix in HPP. Hence, for two unrelated girls with worsening infantile HPP, marrow cell and bone cell transplantation in 2003 and 2007, respectively, seemed beneficial although engraftment of donor cells was low. In 2007, the first of a few case reports appeared of “off-label” use of teriparatide for adult HPP (*J Clin Endocrinol Metab* 92:123–08, 2007).

Treatment (contd.)

■ Medical Treatment (contd.)

In 2012, experimental bone-targeted recombinant TNSALP replacement therapy (asfotase alfa) showed excellent promise for life-threatening HPP. This is a fusion protein that consists of TNSALP, the Fc fragment of immunoglobulin G1, and a deca-aspartate motif for mineral targeting. Marked improvement in the skeletal abnormalities of infants and children with severe HPP was documented radiographically within several weeks or months, and was accompanied by significantly better pulmonary function and developmental motor and cognitive advances.

In HPP children with weakness, the apparent myopathy responds especially quickly. Circulating levels of PLP and PPI diminish. Anti-asfotase alfa antibody levels, when present, were low, and there was no evidence of resistance to this treatment. The experience of one year's duration with this therapy is detailed in a report of 11 patients with perinatal or infantile HPP (*N Engl J Med* 366:904–13, 2012). Clinical trials in children, teenagers, and adults are also underway. Now, an anti-sclerostin antibody is being evaluated in adults with HPP. Further information concerning clinical trial in HPP is available (ClinicalTrials.gov).

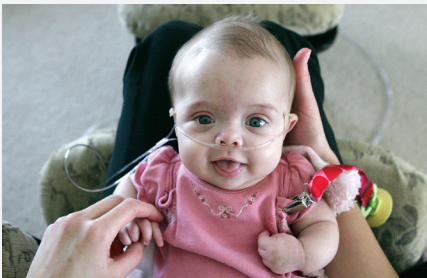
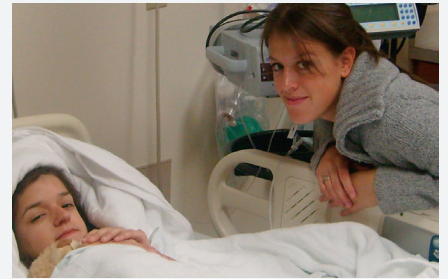
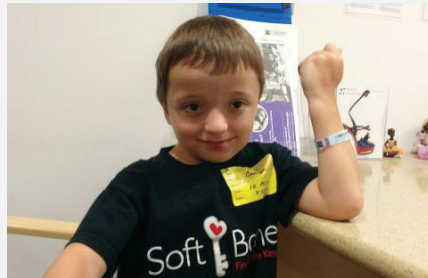
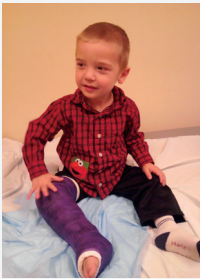
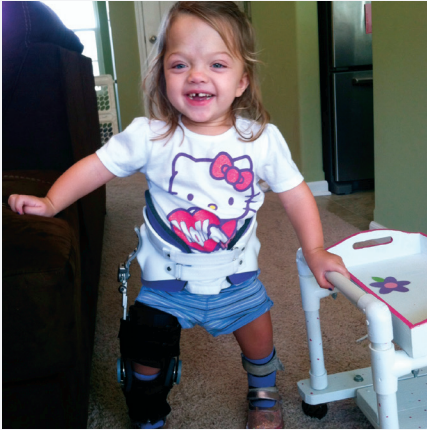
Prenatal Diagnosis

Assay of ALP activity in cord blood *in utero* (cordocentesis) is untested. Historically, assay of ALP activity in amniotic fluid is not useful to diagnose HPP.

Several reports incorrectly considered identification of HPP *in utero* by radiologic techniques to indicate a lethal outcome for the fetus. During the second trimester, perinatal HPP has been diagnosed from ultrasonography (with attention to the limbs as well as to the skull), radiography, and assay of ALP activity in amniotic fluid cells. However, ultrasonography was judged to be normal at 16–19 weeks of gestation in three cases of perinatal HPP in which radiographic studies near term showed absence of a fetal skeleton. Importantly, recent experience with benign prenatal HPP, detailed in 2011, shows that routine ultrasonography cannot predict lethal HPP *in utero* early in the pregnancy. (*JBMR* 26:2389–98, 2011).

Since 1995, *TNSALP* mutation analysis has been used to evaluate pregnancies at risk for lethal HPP. Molecular assessment of *TNSALP* is now available in several commercial laboratories. Although not necessary to make a postnatal diagnosis of HPP, the information is critical for understanding the inheritance pattern of HPP and for prenatal assessments (typically when there has been a previously affected sibling with severe disease). However, characterization of the benign prenatal form of HPP has raised important issues concerning the predictability of the outcome especially for fetuses with defects in both *TNSALP* alleles. In fetuses with benign prenatal HPP, bowing has corrected spontaneously late in the pregnancy as well as postnatally, with the clinical phenotype otherwise then ranging from infantile HPP to odonto-HPP.



Hypophosphatasia patients and family members.

Soft Bones Foundation was formed in 2009 to provide information and a community to educate, empower and connect patients living with HPP, their families and caregivers.

The Foundation also promotes research of this rare bone disease through awareness and fund-raising efforts.

**For more information, please contact
the Soft Bones Foundation.**



(866) 827-9937 – Toll Free • (973) 453-3093 – Direct Line

121 Hawkins Place, #267

Boonton, New Jersey, USA 07005

www.softbones.org





Michael P. Whyte, M.D.

*Medical-Scientific Director,
Center for Metabolic Bone Disease
and Molecular Research*

Shriners Hospital for Children
St. Louis, MO, USA 63131

*Professor of Medicine, Pediatrics, and Genetics,
Division of Bone and Mineral Diseases*

Washington University School of Medicine
St. Louis, MO, USA 63110

Telephone: 314-872-8305

Fax: 314-872-7844

E-mail: mwhyte@shrinenet.org

